



Unknown Primary

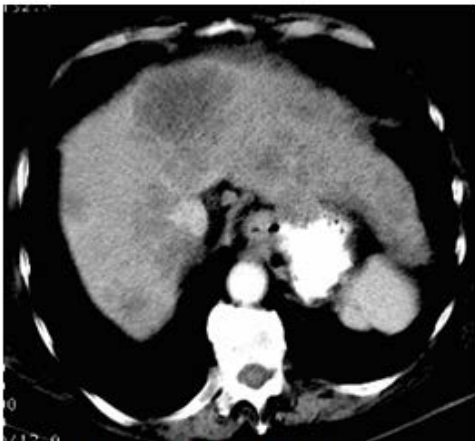

Fig. 1 Abdominal CT

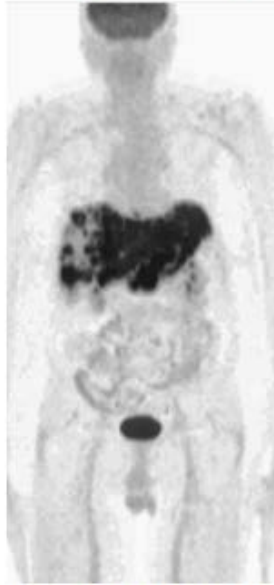


Fig. 2 PET 3 D projection

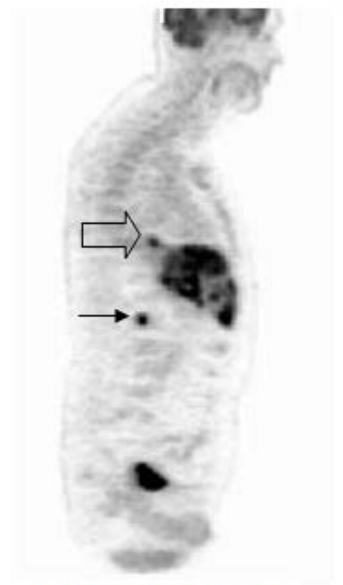


Fig. 3 Sagittal PET

This 73 year old man was complaining of abdominal pain without swallowing difficulty. A CT of the abdomen was obtained which showed multiple hepatic masses suggestive of metastatic disease (Fig. 1). No primary lesion was seen in the abdomen. An FNA of the liver was performed. Cytology showed metastatic adenocarcinoma consistent with a gastric primary tumor.

A PET scan was obtained which showed:

- Sub-total replacement of the liver with tumor (Figs. 2,3)
- Multiple bone metastases (L1 vertebra shown – solid arrow)
- A focus of increased FDG uptake in the posterior low mediastinum suggestive of a distal **esophageal carcinoma** (open arrow)

An EGD was performed. Thickened folds were noted at the esophagogastric junction suggestive of inflammation. Biopsies of the distal esophagus revealed an infiltrating moderately to poorly differentiated adenocarcinoma.

How did the PET-CT help?

The PET identified the primary tumor, which was otherwise asymptomatic and not detectable on the CT.

In a recent study involving 41 patients referred to a PET center for metastasis of unknown primary. PET correctly identified the primary tumor in 26/41 (63%) of the patients .¹

(1)Nucl Med Commun.2003;24:1081-1086